

## Recurrent Transcatheter Aortic Valve Implantation (TAVI) Thrombosis: A Rare Case and Review of Literature

Hassan W\*

Aljareh AW<sup>1</sup>

Mostafa MA<sup>1</sup>

Hassan M<sup>1</sup>

Eldin SS<sup>1</sup>

Bajaber A<sup>1</sup>

<sup>1</sup>Department of Cardiovascular Disease, International Medical center, Jeddah, Saudi Arabia

### Abstract

In this report, we present a case of high risk elderly patient with severe symptomatic aortic stenosis who underwent a transcatheter aortic valve implantation (TAVI) and has been presenting with recurrent TAVI thrombosis. The patient has been treated successfully with anticoagulation. This report will give an updated review of this unusual but serious TAVI complication.

**Keywords:** Transcatheter aortic valve implantation, Thrombosis, Recurrence, Anticoagulation

### Introduction

Recently transcatheter aortic valve implantation (TAVI) have been used as an alternative method for treating aortic stenosis in patients with high or intermediate estimated surgical risk such as previous cardiac surgery or other severe co morbid conditions [1-7].

Antithrombotic therapy in the setting of TAVI has been empirically determined, with the most commonly recommended treatment consisting of unfractionated heparin during the procedure followed by dual anti platelet therapy with aspirin (indefinitely) and clopidogrel for 6 months. Valve thrombosis (VT) following surgical valve replacement is a life-threatening complication largely involving mechanical prostheses and is commonly associated with sub therapeutic oral anticoagulation (OAC) therapy [2]. Bioprosthetic surgical aortic valves rarely thrombose, with an estimated incidence of 0.01% to 1.26%. To date, an estimated 150 000 TAVI procedures or more have been performed worldwide. However, data on this critical complication of TAVI thrombosis is currently limited to isolated case reports or small case series. Herein we present in this report a rare case of recurrent TAVI thrombosis and successful treatment with anticoagulation.

### Case Presentation

The patient is 79 years old with known history of ex smoking, chronic obstructive pulmonary disease, hypertension; non-insulin dependent diabetes mellitus, mild chronic kidney disease, severe dyslipidemia, post cervical discectomy 5 years back, and ischemic heart disease, previous coronary artery bypass grafting (CABG) was done 12 years earlier. The patient had progressive dyspnea and Echocardiography revealed degenerative severe calcific aortic valve stenosis, because of his high Euro score (18%) and STS (26%) score as well as his functioning left internal mammary artery (LIMA) graft he was offered a transcatheter aortic valve replacement (TAVI).

### The TAVI procedure

TAVI was done successfully under only local anesthesia, conscious sedation and using transthoracic echocardiography (TTE). Using 5-French right radial approach for pigtail injection and using right femoral artery as a main site for valve delivery. We used Preclose two ProGlide suture system to the right femoral artery site and we used left femoral vein for temporary pacing. Our

### Article Information

**Article Type:** Case Report

**Article Number:** JCDM107

**Received Date:** 30<sup>th</sup>-January-2018

**Accepted Date:** 28<sup>th</sup>-February-2018

**Published Date:** 20<sup>th</sup>-March-2018

**\*Corresponding author:** Dr. Walid Hassan, MD, FAHA, FCCP, FACC, FACP, FSCAI, Professor of Medicine and Senior Consultant, Director of the Cardiac Center of Excellence, International Medical center, P.O. Box 2172, Jeddah 21451, Saudi Arabia. Tel: + 966-12-650-9000; Email: [whassan@imc.med.sa](mailto:whassan@imc.med.sa)

**Citation:** Hassan W, Aljareh AW, Mostafa MA, Hassan M, Eldin SS, et al. (2018) Recurrent Transcatheter Aortic Valve Implantation (TAVI) Thrombosis: A Rare Case and Review of Literature. J Cardiovas Disea Medic 1:1 (33-38).

**Copyright:** © 2018 Hassan W, et al. This is an open-access article distributed under the terms of the Creative Commons Attribution License, which permits unrestricted use, distribution, and reproduction in any medium, provided the original author and source are credited.

usual antithrombotic therapy during TAVI is anticoagulation with unfractionated heparin to keep the activated clotting time (ACT) 300-350 seconds.

Under temporary pacing, we did first aortic balloon valvuloplasty using Edward #23 mm balloon, then, we decided to proceed with size #26 Edward Sapein bio prosthetic valve which was successfully deployed under fluoroscopy and transthoracic echocardiography with good result figure 1 and 2. The immediate post TAVI invasive hemodynamic and echocardiography Doppler showed complete remission of the trans-aortic valve pressure gradient, no aortic regurgitation and no aortic paravalvular leak. Repeat echocardiography one day post TAVI showed the same satisfactory result figure 3 and he was discharged home on day two post TAVI. The patient was discharged on aspirin 81 mg daily and clopidogrel 75 mg daily to continue for at least 6 months plus his other medications.

The patient had a remarkable improvement post TAVI and became almost asymptomatic after a few days following the procedure.

At his 4 weeks follow up visit he reported recurrence of his dyspnea after initial improvement and he admitted that he did not take his clopidogrel for the last 6 days prior to his clinic appointment. So transthoracic echocardiography was performed that revealed re elevation of the gradients across the prosthesis (peak to peak gradient PPG = 79 mmHg, mean PG = 48 mmHg) figure 4 with the recommendation to proceed with transesophageal echocardiography (TEE). TEE revealed good aortic bioprosthesis apposition, a hazy mass 11 x 5 mm related to the struts of the bioprosthesis (from the ventricular aspect) figure 5-A and 5-B causing high gradients across the aortic valve with no paravalvular leak, so giving the appearance of the mass, its onset and history of interruption of the clopidogrel therapy gave the impression of valve thrombosis due to premature discontinuation of antiplatelet therapy.

However, vegetation over the aortic bioprosthesis was considered in the differential diagnosis but it seemed unlikely as the patient had no fever and all the laboratory markers of infection were normal (leucocytes count, ESR, CRP, blood culture). The struts were well deployed with no fractures. So, we decided to give the patient full anticoagulation starting with unfractionated heparin then oral anticoagulation with warfarin targeting INR between 2.0 to 3.0 IU.

Three weeks follow up visit after anticoagulation revealed a remarkable improvement of his symptoms again, echocardiography showed marked decrease in the mass and the gradients across the aortic valve the PPG decreased to 45 mmHg, and the mean gradient decreased to 27 mmHg figure 6-A and 6-B. The patient was kept on the warfarin with regular follow up of his INR.

After 3 months of compliance to warfarin he discontinued the warfarin without medical advice one month later he presented with recurrence of his exertional dyspnea on minimal exertion so echocardiography was repeated that revealed recurrence of the thrombosis of the aortic bioprosthesis but this time the thrombus is related to the aortic side of the valve bioprosthesis with significantly increased AV gradient the PPG increased to 94 mmHg and mean PG increased to 65 mmHg figure 7-A and 7-B.

Anticoagulation with low molecular weight heparin and warfarin were initialed again, 3 weeks later the gradients dropped to PPG of 45 mmHg and mean PG of 25 mmHg figure 8, no AR. The decision was made to keep him on oral anticoagulation with warfarin for extended period. His last follow up almost 6 months from the second TAVI thrombosis event revealed normal exercise

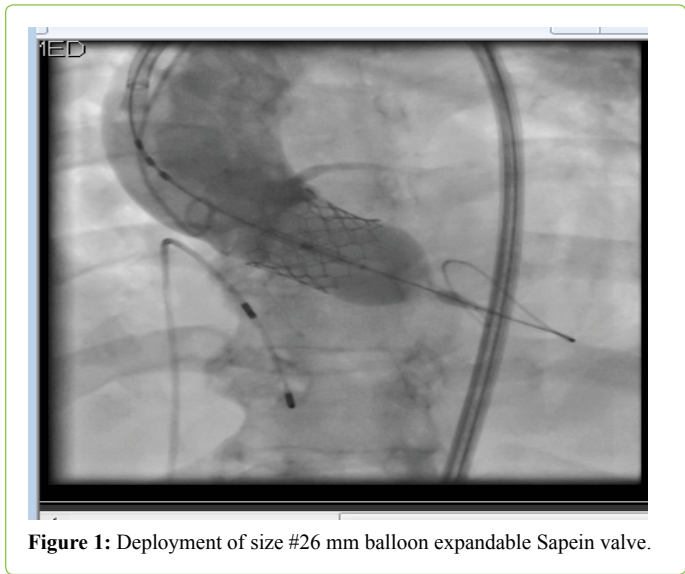


Figure 1: Deployment of size #26 mm balloon expandable Sapein valve.

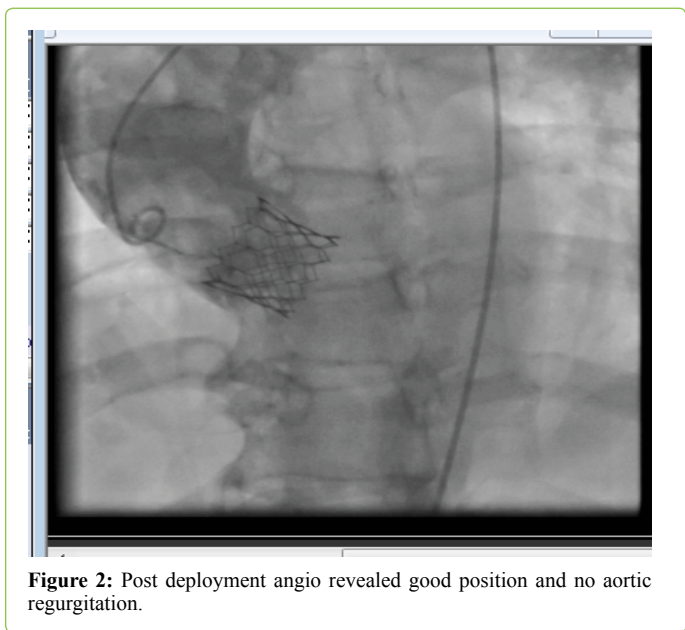


Figure 2: Post deployment angio revealed good position and no aortic regurgitation.

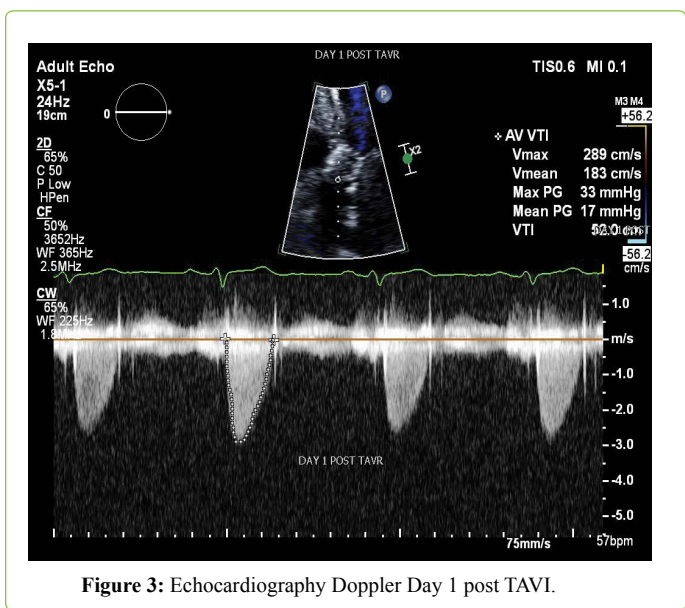
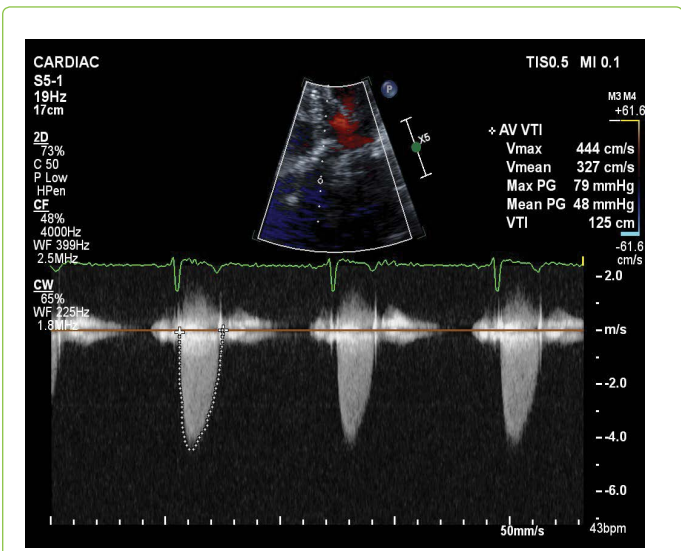
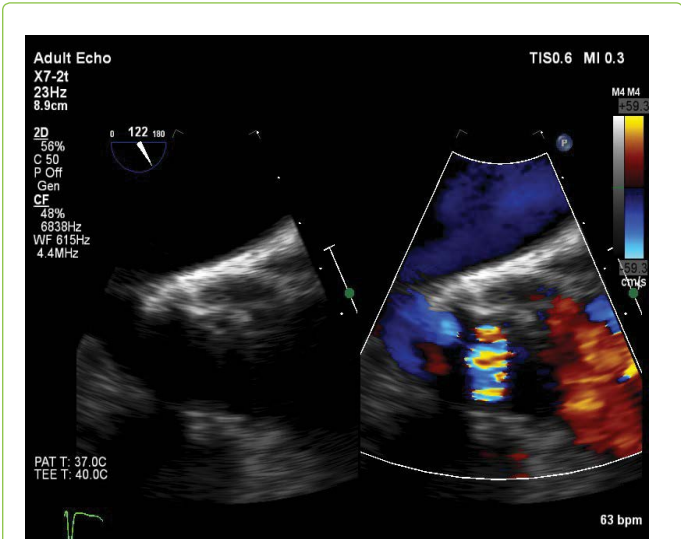


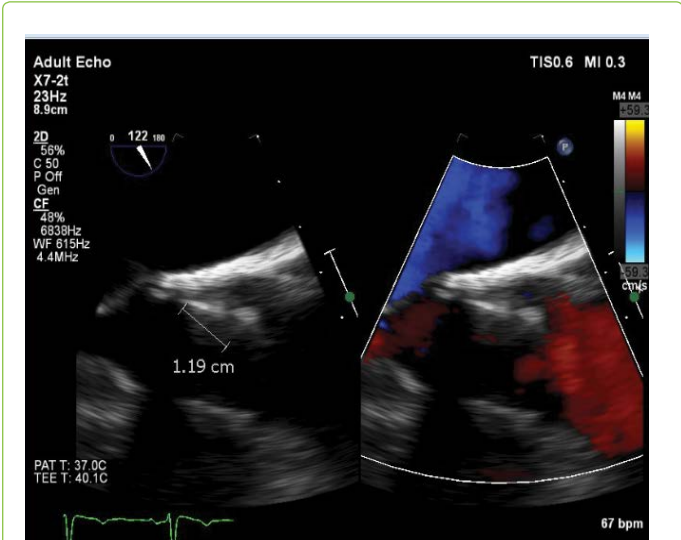
Figure 3: Echocardiography Doppler Day 1 post TAVI.



**Figure 4:** Echocardiography 4 weeks post TAVI revealed increased AV gradient.



**Figure 5-A:** Echocardiography revealed TAVI Thrombus (left ventricular side).



**Figure 5-B:** Echocardiography revealed TAVI Thrombus (left ventricular side).

tolerance with no symptoms and repeat echo showed normal left ventricular systolic function, AV PPG 32 mmHg and mean PG 18 mmHg, no AR or leak, normal mitral, tricuspid and pulmonary pressure.

**Discussion**

The complication profiles of TAVI and surgical aortic valve replacement (SAVR) differ. TAVI is generally associated with lower rates of major bleeding and atrial fibrillation, but higher rates of short-term aortic valve reintervention, pacemaker requirement, and paravalvular aortic regurgitation compared to SAVR [8].

Symptomatic or hemodynamically significant valve thrombosis is rare, occurring in < 1 percent of patients undergoing TAVI [9-12]. Clinical manifestations include exertional dyspnea and increased transvalvular gradients. In such cases, thrombus may or may not be visualized by TTE or TEE.

Proposed mechanisms that increase the risk of TAVI thrombosis include:

- 1) incomplete valve apposition to the aortic wall;
- 2) delayed endothelialization; 3) the metallic frame could potentially provide a site for thrombosis;
- 4) incomplete TAVI expansion can create leaflet folds and potential nidus or recesses for thrombus formation; and 5) the elderly TAVI population might have coexisting hypercoagulable or prothrombotic conditions (e.g., cancer) [9-16]. As well as the premature discontinuation of antiplatelet and anticoagulation therapy as in our case.

Evidence is emerging on the frequency and clinical significance of subclinical valve leaflet thrombosis of bioprosthetic valves following TAVI or SAVR [11-12]. In the largest study to date, 931 patients with bioprosthetic valves enrolled in two registries were studied by a four-dimensional computed tomography (CT) imaging protocol at varying intervals after TAVI or SAVR (median time 83 days); 890 had interpretable CT scans [8]. Subclinical leaflet thrombosis was defined as the presence of reduced leaflet motion along with hypo attenuating valve lesions on CT.

Subclinical leaflet thrombosis was identified in five (4%) of patients with surgical valves and 101 (13%) of 752 patients with transcatheter valves. Subclinical leaflet thrombosis was significantly less frequent among patients receiving anticoagulants (4%) compared with patients receiving dual antiplatelet therapy (15%). Rates were similar with direct oral anticoagulants (DOACs) and warfarin (3 and 4%). Subclinical leaflet thrombosis resolved in all 36 patients treated with anticoagulants (warfarin or DOAC) and persisted in 20 (91%) of 22 patients not treated with anticoagulants [8].

Aortic valve gradients of greater than 20 mmHg and increases in aortic valve gradients of more than 10 mmHg were more frequent among patients with subclinical leaflet thrombosis than among those with normal leaflet motion (14 versus 1 percent). Subclinical thrombosis was associated with significantly increased rates of transient ischemic attacks (TIAs; 4.18 versus 0.6 per 100-person years) and all strokes or TIAs (7.85 versus 2.36 per 100-person years) [8].

We were the first to establish and perform TAVI in the Middle East and Gulf region in 2008 as an alternative method to surgical AV replacement to many patients with severe calcific AS who have very high risk or prohibitive surgical risks [4-6]. Currently, we refined our approach to use only conscious sedation, local anesthesia, transthoracic echocardiography (no general anesthesia,

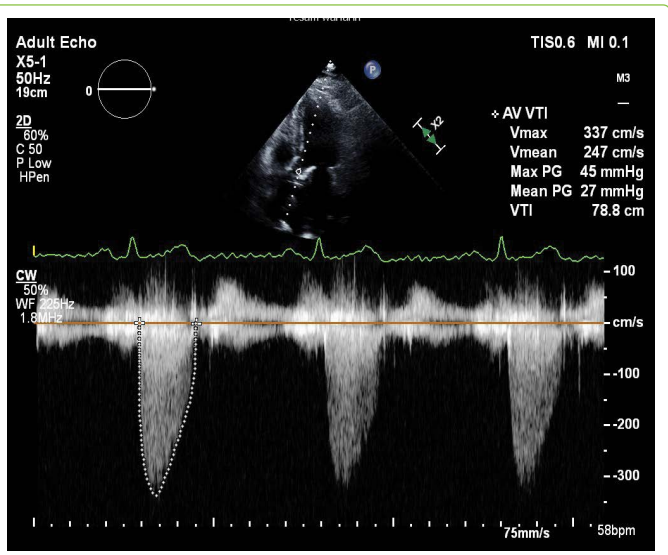


Figure 6-A: Echocardiography Doppler three weeks post anticoagulation.

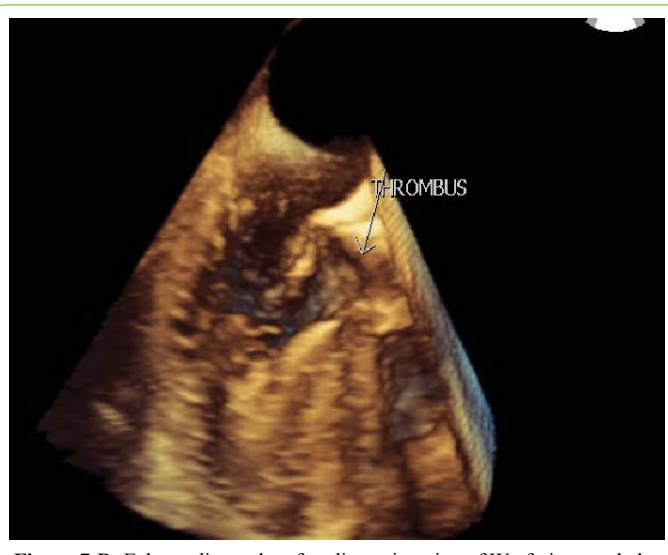


Figure 7-B: Echocardiography after discontinuation of Warfarin revealed TAVI thrombus (aortic side).

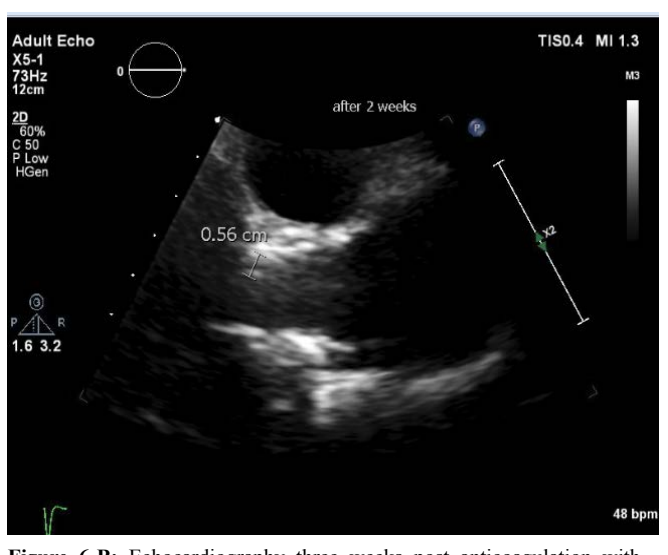

Figure 6-B: Echocardiography three weeks post anticoagulation with decreased thrombus size.

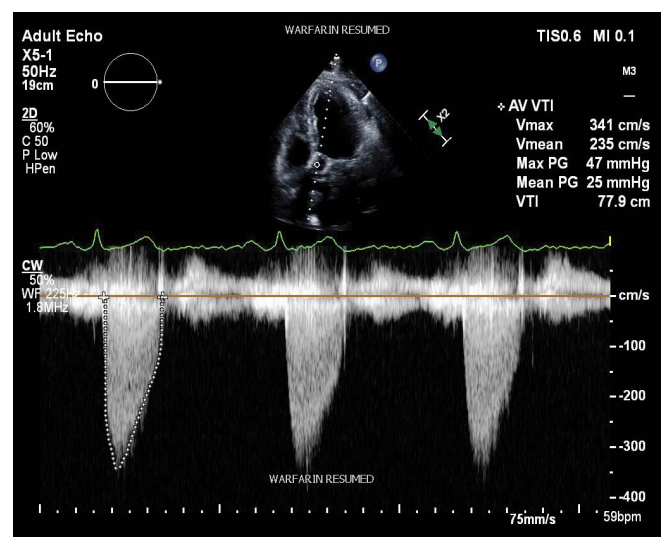


Figure 8: Echocardiography Doppler two weeks post anticoagulation.

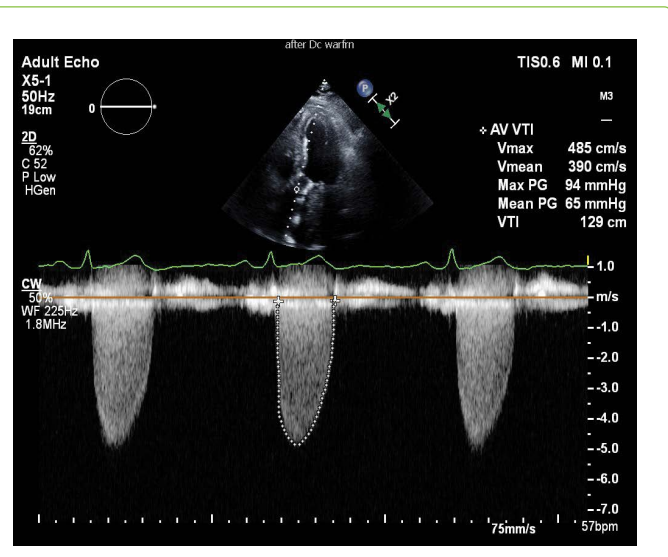


Figure 7-A: Echocardiography Doppler one month after discontinuation of Warfarin.

no intubation, no TEE hence reducing the procedure time and complications) [4]. We also do percutaneous preclose 2 suture devices and no need for arterial cut down. Our usual antithrombotic therapy during TAVI is anticoagulation with unfractionated heparin to keep the activated clotting time (ACT) 300-350 seconds, and post procedure we give dual antiplatelet therapy with aspirin and Clopidogrel for 6 months and Aspirin 81-100 mg indefinitely.

The incidence of valve hemodynamic deterioration (VHD) after TAVI [17, 18], defined as an absolute increase in mean transprosthetic gradient > 10 mmHg between discharge and last follow-up, in a multicenter cohort of 2418 patients was 4.5 percent (overall VHD) and 2.8 percent within the first year (early VHD) [18]. The mean transprosthetic gradient in patients with VHD increased from  $9.5 \pm 5$  mmHg at hospital discharge to  $26.1 \pm 11$  mmHg at follow-up. Independent predictors of transcatheter valve VHD at follow-up included absence of anticoagulation at discharge, Valve-in-valve procedure,  $\leq 23$  mm THV size and increased body mass index. Marked increases in gradients on transthoracic echocardiography post-TAVI invariably imply the possibility of valve thrombosis necessitating empirical oral anticoagulation,

which is often effective at reducing transprosthetic gradients [17].

The type and duration of antithrombotic therapy after TAVI is still controversial. The Current US and European guidelines recommend dual antiplatelet therapy with aspirin and Clopidogrel for 6 months as the standard of care after TAVI and Aspirin 81-100 mg indefinitely but do not recommend routine anticoagulation [11-14]. If there is a new stroke, new increase in the gradient you should have low threshold to screen for TAVI thrombosis either by TEE or even cardiac CT.

Pooled analysis of individual patient data from 672 participants comparing aspirin alone versus dual antiplatelet therapy after TAVI showed no difference in the rate of 30-day net adverse clinical and cerebral events, but a trend toward less life-threatening and major bleeding was observed in favor of aspirin alone [10].

Further investigation is required to determine the incidence, clinical significance, and appropriate management of subclinical bioprosthetic valve (including transcatheter valve) leaflet thrombosis. Ongoing studies (ARTE [Aspirin versus Aspirin + Clopidogrel Following Transcatheter Aortic Valve Implantation], AUREA [The dual Antiplatelet Therapy versus oral Anticoagulation for a short time to prevent cerebral Embolism After TAVI], and POPULAR-TAVI [The Antiplatelet Therapy of Patients Undergoing Transcatheter Aortic Valve Implantation]) will help addressing the issue of antiplatelet post-TAVI. Two ongoing studies will try to answer the potential benefits of oral anticoagulation therapy (GALILEO [Global multicenter, open-label, randomized, event-driven, active controlled study comparing a rivaroxaban-based antithrombotic strategy to an antiplatelet-based strategy after transcatheter aortic valve replacement Optimize clinical outcomes] and ATLANTIS [Anti-Thrombotic strategy to Lower All cardiovascular and Neurologic ischemic and hemorrhagic events after Trans-aortic valve Implantation for aortic Stenosis]).

But the question is when should we start anticoagulation and for how long it should be given? (2017 ESC just came out) there is no guidelines delineating the management of this complication. We suggest keeping the patient on anticoagulation until the disappearance of the thrombus as well as dropping of the gradients back to the baseline.

In Our case of the recurrent post TAVI thrombosis we had a highly suspected culprit following premature discontinuation of dual antiplatelet therapy in the first follow up then after self-discontinuation of warfarin in the second follow up which is not uncommon to happened among post TAVI patients where most of them are elderly and compliance with medications is an issue for them. Fluoroscopy and TEE showed a well expanded valve stent, no struts fracture or paravalvular leak.

Possible invention of a stent which needs no antiplatelet or anticoagulation will lead to much better outcome in the future, but for the time being, we highly encourage our colleagues in the field of interventional cardiology with TAVI practice to establish a data base for reporting post TAVI thrombosis complication cases and to study this phenomena closely, and conduct different researches to establish clear guidelines for optimal antithrombotic therapy for TAVI patients which will tremendously add on to the current new era of TAVI practice.

Finally, the presence of several co morbidities in those elderly TAVI cases like; atrial fibrillation, mitral mechanical valve, and renal impairment makes the choice of antithrombotic and anticoagulation therapy more challenging.

## Conclusions

Transcatheter aortic valve (TAVI) thrombosis is a rare but

serious complication which needs special attention in recognition and management. The choice and duration of treatment with either anticoagulation and/or antiplatelet therapy is still evolving. The continuous improvement and refining of new generation of valve prosthesis and stents as well as ongoing and future researches for optimal therapy might expand our understanding of this intriguing TAVI complication and should have a favorable ramification with this issue of TAVI thrombosis.

TAVR is therapy evolving toward its maturation. The antithrombotic therapy after the procedure and its duration are to be settled by randomized trials. Currently, the type and the duration of the antithrombotic therapy must be personalized toward the patient's need.

## References

- Leon MB, Smith CR, Mack M, Miller DC, Moses JW, et al. (2010) Transcatheter Aortic-Valve Implantation for Aortic Stenosis in Patients Who Cannot Undergo Surgery. *N Engl J Med.* 363: 1597-1607.
- Kapadia SR, Leon MB, Makkar RR, Tuzcu M, Svensson LG, et al. (2015) 5-year outcomes of transcatheter aortic valve replacement compared with standard treatment for patients with inoperable aortic stenosis (PARTNER 1): a randomised controlled trial. *The Lancet* 385: 2485-2491.
- Duncan A, Ludman P, Banya W, Cunningham D, Marlee D, et al. (2015) Long-term outcomes after transcatheter aortic valve replacement in high-risk patients with severe aortic stenosis: the U.K. Transcatheter Aortic Valve Implantation Registry. *JACC Cardiovasc Interv.* 8: 645-653.
- Hassan W, Lhmdid M, Hassan M, Katabi M, Mostafa M (2017) Improvement of Angiodysplasia- derived anemia after Transcatheter aortic valve implantation: A case report and literature review. *J Hypertens Curr Concepts Ther.* 1: 1-3.
- Hassan W, Elwatidy A, Kassab S, et al. (2011) First Middle East Transcatheter Aortic Valve Implantation (TAVI) Experience: Immediate and 20 Months Follow-Up. *Catheter Cardiovasc Interv.* 77: 139.
- Elwatidy A, Hassan WM, Kassab S, et al. (2011) First Middle East Transcatheter Aortic Valve Implantation (TAVI) Experience: Immediate and 18 Months Follow-Up. *J Am Coll.* 57: 90.
- Siemieniuk RA, Agoritsas T, Manja V, Devji T, Chang Y, et al. (2016) Transcatheter versus surgical aortic valve replacement in patients with severe aortic stenosis at low and intermediate risk: Systemic review and meta-analysis. *BMJ.* 354: i5130.
- Chakravarty T, Søndergaard L, Friedman J, Backer OD, Berman D, et al. (2017) Subclinical leaflet thrombosis in surgical and transcatheter bioprosthetic aortic valves: an observational study. *The Lancet.* 389: 2383-2392.
- Mylotte D, Andalib A, Thériault-Lauzier P, Dorfmeister M, Girgis M, et al. (2015) Transcatheter heart valve failure: a systematic review. *Eur Heart J.* 36: 1306-1327.
- Gargiulo G, Collet J.P, Valgimigli M (2015) Antithrombotic therapy in TAVI patients: changing concepts. *EuroIntervention.* 11: W92-W95.
- Latib A, Maganuma T, Abdel-Wahab M, Danenberg H, Cota L, et al. (2015) Treatment and clinical outcomes of transcatheter heart valve thrombosis. *Circ Cardiovasc Interv.* 8: e001779.
- De Marchena E, Mesa J, Pomenti S, Kall CMY, Marincic X, et al. (2015) Thrombus formation following transcatheter aortic valve replacement. *JACC Cardiovasc Interv.* 8: 728-739.
- Nishimura R.A, Otto C.M, Bonow R.O, Carabello BA, Erwin III JP, et al. (2014) 2014 AHA/ACC guideline for the management of patients with valvular heart disease: a report of the ACC/AHA Task Force on Practice Guidelines. *J Am Coll Cardiol.* 63: e57-e185.
- Trantalís G, Toutouzas K, Latsios G, Synetos A, Brili S, et al. (2017) TAVR and thrombosis. *JACC: cardiovasc imag.* 10: 86-87.
- Hasson NC, Grave EL, Andersen HR, Leipsic J, Mathiassen ON, et al.

- (2016) Transcatheter Aortic Valve Thrombosis: Incidence, Predisposing Factors, and Clinical Implications. *J Am col cardiol.* 68: 2059-2069.
16. Makkar RR, Fontana G, Jilaihawi H, Chakravarty T, Kofoed KF, et al. (2015) Possible subclinical leaflet thrombosis in bioprosthetic aortic valves. *N Engl J Med.* 373: 2015-2024.
17. Del Trigo M, Muñoz-García AJ, Wijeyesundera HC, Nombela-Franco L, Cheema AN, et al. (2016) Incidence, Timing, and Predictors of Valve Hemodynamic Deterioration After Transcatheter Aortic Valve Replacement: Multicenter Registry. *J Am Coll Cardiol.* 67: 644-655.
18. Baumgartner H, Falk V, Bax JJ, Bonis MD, Hamm C, et al. (2017) 2017 ESC/EACTS Guidelines for the management of valvular heart disease. *Eur Heart J.* 38: 2739-2791.